



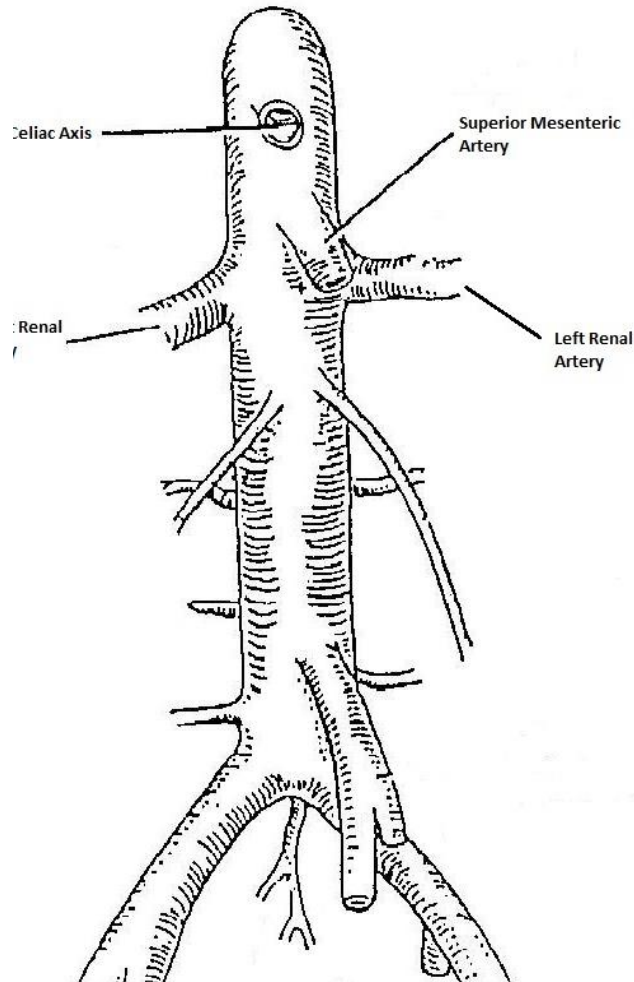
CARDIORISK AAA SCREENING

Patient Name: GRANT, REBECCA Date: 12-08-2023

DOB: 09/28/1956 Sex: F

Referring Provider: SCOTT BELL

Vascular Technician: MICHELE WALTERS



Aorta Prox

2.7 cm Trans X 2.6 cm AP

Aorta Mid

1.7 cm Trans X 1.6 cm AP

Aorta Distal

1.7 cm Trans X 1.8 cm AP

Comments: No Abdominal Aortic Dilatation / Aneurysm was identified in the submitted images. There was a small amount of calcified plaque identified in the Abdominal Aorta.



